

Keywords

CBCT; Mandibular incisors; Root canal configuration; Symmetry; Vertucci classification

Authors

Ala Mahdi Muhamed Ali.^{1*}
MSc, PhD conservative dentistry.
Lecturer at college of dentistry,
university of Kerbala,
Iraq.alaa.m@uokerbala.edu.iq

Ali S. Al-Haddad.²

MSc oral and maxillofacial radiology.
Assistant professor at College of
Dentistry, University of Kerbala, Iraq.

Sundus Mohammed Ali Al-Bazi.³

MSc preventive dentistry. Assistant
lecturer at department of Dentistry, Al-
Zahrawi University College, Iraq

Rafid J. Al-Badr.⁴

MSc, PhD conservative dentistry.
Lecturer at college of Dentistry, Ahl
AL Bayt University, Iraq.

Evaluating Root Canal Morphology of Permanent Mandibular Incisors Using CBCT in a Sample of Iraqi Population (Middle Euphrates Region)

Abstract

Background/purpose: The objective of the study was to establish the morphology of the root canal space of permanent mandibular incisors in one of the samples of the population of Karbala governorate in Iraq by using cone-beam computed tomography (CBCT) images.

Materials and methods: 263 CBCT images were used in this study, 980 of which were of mandibular incisors. The number of roots, root canals, and root canal configurations was statistically assessed and analyzed according to Vertucci. Also, the root canal configuration gender prevalence was evaluated.

Findings: The number of roots in all the studied incisors was one. One canal was observed in about 66.43% of the teeth, with 33.57% having two canals. The mean difference between males and females, as well as the central and lateral incisors, was statistically non-significant (p -value < 0.05). Types I, II, III, and V of the vertical canals were identified; the first type (66.43%), the third type (30.2%), and the second type (3.27%) were the most common types, but type V was identified only once (0.1%). Central incisors and lateral incisors were observed to have a high level of bilateral symmetry in terms of canal number (89.12% and 88.84%, respectively).

Conclusion: There are two root canals in different configurations in approximately one-third of mandibular incisors in Karbala governorate. These results are similar to the ones found in the Iraq-Kurdistan area.

Introduction

Anatomical knowledge of the root canal system (RCS) significantly impacts the practice of endodontics in a clinical setting. The ultimate goal of endodontists is to achieve a hermetic seal of the RCS after completely removing the vital and/or necrotic pulp tissue, microorganisms, and their byproducts. However, this task could be challenging to accomplish in reality because of the complexity of the RCS. Many studies have shown that RCS comprise complex passageways for pulp tissue that split and unite from the orifice to the root apex [1-4]. Detailed data about the number of roots, number of canals, inner canal configuration, and possible variations in all groups of teeth is a prerequisite for a successful root canal treatment outcome [5, 6]. Studies have shown a significant difference in the root canal configuration of human teeth among different populations [2, 6].

In the past, several methods have been performed to study the morphology of RCS in human teeth, mostly on extracted teeth using techniques like tooth clearing [7,8], cross-sectioning [9], and radiographs with intracanal contrast medium [10]. Recent technological advances have allowed the production three-dimensional (3D) tomographic images with high-resolution of human teeth and surrounding structures. CBCT is a noninvasive technique that allows studies to be conducted using a larger sample population [6] and is considered as

appropriate

..... EJPRD

Received: 02.01.2026
Revised: 15.01.2026
Accepted: 23.01.2026
Doi:10.1922/ejprd.v34i2.1332

as the root-clearing and canal staining techniques in categorizing root canal systems [11].

Mandibular incisors mostly have one root with a long, narrow single canal. However, occasionally, one canal branches into two canals, rejoining into a single canal before reaching the apex, or they may persist as two separate canals [12]. While studies have utilized CBCT to evaluate the root canal configuration of permanent mandibular anterior teeth in an Iraqi-Kurdistan subpopulation [13-15], to the best of our knowledge, there is currently no available study assessing the root canal configuration of permanent mandibular incisors in other regions of Iraq. Therefore, this study was conducted using CBCT to determine the prevalence of the common root canal configuration of mandibular incisors in the Iraqi Middle Euphrates subpopulation.

Materials and Methods

The patient's sample

This retrospective cross-sectional study was performed on CBCT images of 263 patients (113 males and 150 females) obtained from a private clinic of oral and maxillofacial radiology in Karbala governorate. The ages of the patients ranged from 14 to 65 years old. All CBCT scans were requested for variable surgical, orthodontic, endodontic, restorative, and prosthetic treatment from January 1, 2023, to December 31, 2024. Authorization to use the CBCT images in this study was collected from the director of the radiology clinic, and ethical permission was obtained from the ethical committee at the College of Medicine, University of Kerbala. All image data sets were obscured to keep the patients' identities trustworthy.

Images included in this study contained at least one of the permanent mandibular incisors (central or lateral); the teeth must be sound with fully developed roots and no previous endodontic treatment or pathologies.

CBCT examination

A specialized oral and maxillofacial radiologist exclusively performed CBCT scans. The CBCT

images were obtained using a Hyperion X5® (Myray, Imola (Bo), Italy) operating at 8 mA and 90 kV, with variant field-of-view (FOV), according to the needs of the case, extending from 40 × 40 mm to 80 × 80 mm. The voxel size was 0.125 mm.

Image analysis

Two examiners (a radiologist and an endodontist) assessed each image using the MyRay iRYS software viewer program, utilizing all software enhancements, such as zooming and changing brightness and contrast. Each tooth was evaluated in the axial, coronal, and sagittal planes with a cutting interval of 0.125 mm to get the final result of canal configuration. In cases where an agreement was not achieved, a third opinion from a specialized oral radiologist was requested to achieve a conclusive assessment regarding canal configuration. Canal configuration was categorized following the criteria of Vertucci [16] (Figure 1):

1. Type I: One pulp canal that extends from the pulp chamber to the root apex.
2. Type II: Two distinct pulp canals extend from the pulp chamber but unite into one before reaching the root apex.
3. Type III: One pulp canal extends from the pulp chamber, splits into two within the root, and then unites into one before reaching the root apex.
4. Type IV: Two distinct pulp canals extend from the pulp chamber to the root apex.
5. Type V: One pulp canal extends from the pulp chamber but splits into two before reaching the root apex.
6. Type VI: Two distinct pulp canals extend from the pulp chamber, unite into one within the root and then split into two before reaching the root apex.
7. Type VII: One pulp canal extends from the pulp chamber, splits and reunites within the root, and splits again into two distinct canals before reaching the root apex.
8. Type VIII: Three distinct pulp canals extend from the pulp chamber to the root apex.



Figure 1: Vertucci's classification of root canal configuration

Results

After analyzing 263 CBCT scans from patients (113 males and 150 females), no significant difference was found between the genders (t-value 0.19702, p-value 0.43101 at $p < 0.05$). The study evaluated 483 mandibular permanent central incisors and 497

mandibular permanent lateral incisors, all of which were found to have single roots. Regarding the number of canals, 651 teeth (66.43%) had a single canal, with 265 in males and 386 in females, distributed as 321 in mandibular central incisors and 330 in mandibular lateral incisors. Meanwhile, 329 teeth (33.57%) had two canals, with

144 in males and 185 in females, distributed as 163 in mandibular central incisors and 166 in mandibular lateral incisors, as shown in Table 1. The difference

between the central and lateral incisors regarding the presence of two canals was non-significant (t-value - 0.04127, p-value 0.485415 at p-value < 0.05).

Table 1: Canal numbers in mandibular incisors in CBCT scans according to tooth type and patient gender

Tooth/Gender	Canals number		
	One canal	Two canals	Total
Central incisors	321 (66.32%)	163 (33.68%)	484
Lateral incisors	330 (66.53%)	166 (33.47%)	496
Total	651 (66.43%)	329 (33.57%)	980 (100%)
Male	265 (64.8%)	144 (35.2%)	409
Female	386 (67.6%)	185 (32.4%)	571
Total	651 (66.43%)	329 (33.57%)	980 (100%)

Concerning Vertucci's classification, type I and type II were shown in 32 cases (14 cases in central incisors and 18 cases in lateral incisors; 18 were males and 14 were females). Vertucci classification type III appeared in 296 cases (149 in central incisors and 147 in lateral incisors; 125 were males, and 171 were females). Vertucci classification type V in this study appeared just in one mandibular lateral incisor male person, as shown in Figure 2 and Table 2.

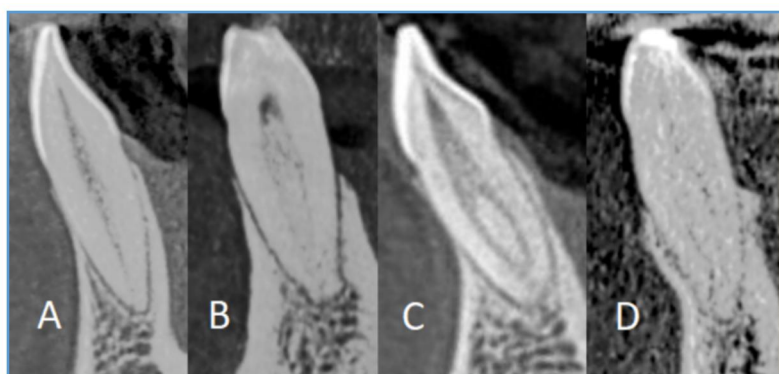


Figure 2: CBCT sagittal view of mandibular incisors: (A) type I; (B) type II; (C) type III; and (D) type V Vertucci classification.

Table 2: Distribution of Vertucci classification

Vertucci's classification	Central incisors		Lateral incisors		Total	
	Count (%)	M ^a / F ^b (%)	Count (%)	M / F (%)	Count (%)	M / F (%)
Type I	321 (66.32%)	M ^a 124 (62.95%) F ^b 197 (68.64%)	330 (66.53%)	M 141 (66.51%) F 189 (66.55%)	651 (66.43%)	M 265 (64.79%) F 386 (67.6%)
Type II	14 (2.89%)	M 8 (4.06%) F 6 (2.09%)	18 (3.63%)	M 10 (4.72%) F 8 (2.82%)	32 (3.27%)	M 18 (4.4%) F 14 (2.45%)
Type III	149 (30.79%)	M 65 (32.99%) F 84 (29.27%)	147 (29.64%)	M 60 (28.3%) F 87 (30.63%)	296 (30.2%)	M 125 (30.56%) F 171 (29.95%)
Type V	0 (0%)	M 0 (0%) F 0 (0%)	1 (0.2%)	M 1 (0.47%) F 0 (0%)	1 (0.1%)	M 1 (0.24%) F 0 (0%)
Total	484 (100%)	M 197 F 287	496 (100%)	M 212 F 284	980 (100%)	M 409 F 571

^amale; ^b female.

Regarding the similarity between right and left mandibular incisors, only patients with bilateral teeth were included in the comparison. Central incisors showed 89.12% symmetry in root canal configuration, while lateral incisors showed 88.84% symmetry in root canal configuration, as shown in Table 3.

Table 3: Numbers and percentages of symmetry of root canal configurations in mandibular incisors

Tooth	Number of symmetrical cases	Total cases
Central incisors	213 (89.12%)	239
Lateral incisors	215 (88.84%)	242

Discussion

Researchers have shown anatomical variation among different populations regarding pulp space

configurations of mandibular anterior teeth [3,13-28], as shown in Table 4. These differences could be attributed to racial and ethnic origins [29-31]. Awareness of the typical morphology of the RCS among people in each geographical region can decrease errors during root canal procedures. This study explored root canal morphology and the presence of a second canal in permanent mandibular incisors amongst residents of the Middle Euphrates region in Iraq. Different studies have confirmed that missed canals harm the outcome of endodontic treatment [32, 33]. The RCS of the permanent mandibular incisors is

comparable to that when they are examined together. These teeth often have two canals located labially and lingually, frequently missing the lingual canal [12]. If a single of the present two canals is treated, the pulp tissue of the additional canal becomes necrotic and yields toxic agents, which can spread to the periodontal ligament through the main, lateral, and accessory canals. In several studies, CBCT has been commonly used to identify canals' morphologies because it is a precise and noninvasive method that allows more people to be examined [34, 35].

Table 4: Percentages of root canal configurations found in permanent mandibular incisors in previous studies assessed by CBCT

Author Year	Country	Tooth	Sample size	Percentage of canal configuration									
				I	II	III	IV	V	VI	VII	∞		
Aminsobhani et al. ¹⁸ 2013	Iran	Central incisor	632	72.7	11.3	4.7	7.7	3.6	0	0	0	–	
		Lateral incisor	614	70.6	7.1	3.7	15.4	3.2	0	0	0	–	
Liu et al. ¹⁹ 2014	China	Central incisor	768	91.1	2	5.3	1.3	0.3	0	0	0	–	
		Lateral incisor	785	82.5	3.9	10.4	2.8	0.3	0	0	0	–	
Leoni et al. ²⁰ 2014	Brazil	Central incisor	50	50	0	28	0	0	–	4	0	18	
		Lateral incisor	50	62	0	28	0	0	–	2	0	8	
Lin et al. ²¹ 2014	China	Central incisor	706	89.1	2.4	6.2	1.7	0.6	0	0	0	–	
		Lateral incisor	706	74.5	3.7	19.3	2.1	0.4	0	0	0	–	
Arslan et al. ²² 2015	Turkey	Central incisor	185	51.9	4.3	41.6	0	0.5	0	0	0	1.6	
		Lateral incisor	189	52.9	2.6	42.3	0	1.6	0	0	0	0.5	
Kamtane & Ghodke ²⁴ 2016	India	Mandibular incisors	102	64.71	23.53	8.82	2.94	0	0	0	0	–	
Basha ²⁵ 2018	Egypt	Central incisor	200	M _a	76	0	17	0	7	0	0	0	–
				F ^b	95	0	5	0	0	0	0	0	–
		Lateral incisor	200	M	88	0	7	0	5	0	0	0	–
				F	91	0	9	0	0	0	0	0	–
Popovic et al. ²⁶ 2018	Serbia	Central incisor	296	73	4.7	21.6	0	0.7	0	0	0	–	
		Lateral incisor	294	73.5	5.4	18.4	0.7	2	0	0	0	–	
Valentini-Obino et al. ²⁷ 2019	Italy	Central incisor	487	55	34.3	9.3	0.6	0	0	0.8	0	–	
		Lateral incisor	491	57	35.7	6.9	0	0	0	0.4	0	–	
Mirhosseini et al. ³ 2019	Iran	Central incisor	330	76.1	0	15.8	0.6	7.6	0	0	0	–	
		Lateral incisor	351	65	0.6	15.7	0.9	17.9	0	0	0	–	
Ghabbani et al. ²⁸ 2021	Saudi Arabia	Mandibular incisors	1624	50.3	0	42.3	0.2	5.3	0	1.6	0	–	

Dizayee & Selman ¹⁴ 2019	Iraq Kurdistan	Mandibular incisors	1716	79.254	0.466	20.279	0	0	0	0	0	–
Goran & Rofoo ¹⁵ 2020	Iraq Kurdistan	Central incisor	388	67	1	22.6	0	7.7	0	1.8	0	0
		Lateral incisor	388	67	0.5	18	0	13.9	0	0.7	0	0
Talabani ¹⁶ 2021	Iraq Kurdistan	Central incisor	597	73.8	18	8	0	0	0	0	0	–
		Lateral incisor	599	71.2	12.8	6.8	0	0	0	0	0	–
Present study	Iraq Karbala	Central incisor	484	66.32	2.89	30.79	0	0	0	0	0	–
		Lateral incisor	496	66.53	3.63	29.64	0	0.2	0	0	0	–

§ New root canal configurations are not included in Vertucci's classification [21, 23].

^a male; ^b female.

The Vertucci classification was used in the current study because it is reasonably inclusive, accessible to apply, and most commonly used in previous studies (Table 4).

In this research, only types I, II, III, and V of Vertucci canal configurations were noticed in mandibular incisors. Vertucci type I canal configuration was the most dominant, which was in harmony with preceding studies in Iraq [13-25] and in different countries [3, 19, 21, 24-26]. Based on the current study's findings, the prevalence of two canals in mandibular incisors was 33% and 57%. These findings are very comparable to those of **Goran & Rofoo** [14] (33.1%), who conducted their study in the Kurdistan region of Iraq, while the results differ slightly from the findings of two studies by **Dizayee & Selman** [13] (20.75%) and **Talabani** [15] (26.1-30.4%), which were conducted in the same region.

Vertucci type III canal configuration was the next most prevalent, whereas type V canals were marginally least prevalent. Nevertheless, this finding aligns with the research conducted by **Liu et al.** [19], **Lin et al.** [21], and **Arslan et al.** [22] and is to some extent consistent with the conclusions drawn by **Popovic et al.** [26], **Mirhosseini et al.** [3], **Dizayee & Selman** [13], **Goran & Rofoo** [14], and **Ghabbani et al.** [28]. However, it contradicts the findings of **Aminsobhani et al.** [18], **Kamtane & Ghodke** [24], **Valenti-Obino et al.** [27], and **Talabani** [15].

Studying bilateral symmetry in root canal configuration is clinically significant as it may help the clinician to predict, with high probability, the corresponding tooth configuration on the contralateral side [28, 36, 37]. Among the population of the current study, the overall symmetry in the configuration of the root canal was more common in central incisors (89.12%) than in lateral incisors (88.84%). These results came in agreement with **Lin et al.** [21], who found that the overall symmetry in the root canal configuration was (92.7%) for central incisors and (89.2%) for lateral incisors. Nevertheless, several studies showed a high degree of variation with a low or high percentage of symmetry in the configuration of equivalent teeth on the contralateral side [16, 27]. These

differences could be attributed to ethnic differences or a variable sample size.

Conclusions

All mandibular permanent incisors have single roots, but 33.57% have two root canals with non-significant differences between central and lateral incisors or between males and females. Vertucci type I canal configuration was the most predominant, and the least was type V, while type IV was not found. Finally, there was a high degree of bilateral symmetry due to two root canals.

Conflicts of Interest

The authors have no conflicts of interest related to this study.

Acknowledgments

We are deeply grateful to the manager and the staff of the radiology clinic in Karbala (Al-Mina dental clinics), who helped to conduct this study.