

A Retrospective Clinical Study on 1075 Lithium Disilicate CAD/CAM Veneers with Feather-Edge Margins Cemented on 105 Patients

Keywords

Lithium Disilicate (LiDiSi)
Computer-Aided-Design/Computer-Assisted-Manufacturing (CAD/CAM)
Veneers
Feather-Edge Margins

Authors

Mario Imburgia *
(DDS, PhD)

Henriette Lerner §
(DDS)

Francesco Mangano †
(DDS, PhD)

Address for Correspondence

Francesco Mangano †

Email: francescomangano1@mclink.net

* Private Practice, Palermo, Italy

§ Private Practice, Baden-Baden, Germany

† Department of Prevention and Communal Dentistry, Sechenov First State Medical University, Moscow, Russia

ABSTRACT

Purpose: To evaluate the clinical performance of lithium disilicate (LiDiSi) computer-aided-design/computer-assisted-manufacturing (CAD/CAM) veneers with feather-edge margins. *Methods:* Over 4 years (2015–2019), 1075 LiDiSi veneers with feather-edge margins were fabricated with a fully digital workflow and cemented on 105 patients. The outcome variables were survival of the restorations, colour matching, quality of the ceramic surface, presence of marginal discolouration and marginal integrity. The last four variables were assessed using the modified California Dental Association (CDA) and Ryge criteria. *Results:* The mean observation period was 30.8 months. The cumulative survival rate was 99.83%. At the last follow-up control, the colour matching of the surviving 1074 restorations was rated Alpha (1064 veneers, 99.06%) and Bravo (10 veneers, 0.94%); the ceramic surface was rated Alpha (1070 veneers, 99.62%) and Bravo (4 veneers, 0.38%); the marginal discolouration was rated Alpha (1069 veneers, 99.53%) and Bravo (5 veneers, 0.47%); and the marginal integrity was rated Alpha (1070 veneers, 99.62%) and Bravo (4 veneers, 0.38%). *Conclusion:* CAD/CAM LiDiSi veneers with feather-edge margins fabricated with a fully digital workflow showed good clinical performance in terms of survival, colour matching, ceramic surface, marginal discolouration and integrity. Further, prospective and long-term studies are needed to confirm these positive results.

INTRODUCTION

Among the options available to the clinician for minimally invasive aesthetic restorations, porcelain laminate veneers (PLV) represent a solution with a high survival and success rate.¹⁻⁴ PLV veneers guarantee an excellent aesthetic result thanks to the colour stability; they have good biocompatibility and adequate mechanical properties.¹⁻⁴ Because minimal invasiveness is one of the objectives of modern dentistry, full ceramic restorations with minimal thicknesses find an ideal indication.⁵⁻¹³

In its monolithic form, individualised through colouring techniques, lithium disilicate (LiDiSi) is an ideal material in case of abrasion or erosion, or where it is necessary to replace or restore the damaged enamel through a “re-enamelling” process.¹⁴⁻¹⁶ LiDiSi is also indicated for the correction of diastemas or dental malpositions and the restoration of incongruous shapes or colours, due to the presence of extended low-quality composite fillings.

Received: 26.10.2020

Accepted: 20.12.2020

doi: 10.1922/EJPRD_2248Mangano10

LiDiSi is available in the hot-pressed form or blocks for computer-aided-design/computer-assisted-manufacturing (CAD/CAM) with a crystalline phase consisting of LiDiSi and lithium orthophosphate, which increases strength without negatively influencing colour and translucency.^{17–20} The biaxial flexural strength is 407 ± 45 MPa.^{17–20} Usually, LiDiSi is used for monolithic restorations or as a support for porcelain restorations.^{17–20}

IPS Empress 2^{®21,22} and the new IPS e.max[®] CAD^{23,24} (both produced by Ivoclar Vivadent) are LiDiSi-based ceramic blocks for milled CAD/CAM restorations. CAD/CAM-milled LiDiSi restorations offer three advantages: they allow a completely digital workflow, without any traditional impression using trays and materials; they do not require any manual procedure; they are characterised by high clinical predictability.^{23–26} In conventional, metal-free restorations, the most-used type of prosthetic preparation is the horizontal one with a well-defined margin: chamfer, shoulder or light chamfer. Preparations without a defined margin are described as knife-edge, feather-edge, shoulderless, or, more simply, as vertical preparations, precisely to differentiate them from the classic horizontal preparations.

Vertical preparations are indicated in perio-prosthetic rehabilitations²⁷ for metal-ceramic restorations in the literature. In contrast, few studies have reported on the results of using full-ceramic crowns with feather-edge preparation.^{28–30} Although horizontal preparation has always been indicated as the ideal for glass-ceramic material, feather-edge or vertical preparations have been used by clinicians in an “unconscious” way. For example, vertical preparations have been used in the case of additive ceramic restorations that exploit the opportunity to cement adhesively etchable dental ceramic to the tooth structure. By nature, these restorations have a very thin margin, almost like feather-edge preparations; these additional restorations are often made with feldspathic ceramics, which exhibit lower biomechanical characteristics than LiDiSi.

For an extremely conservative approach, the use of LiDiSi with vertical preparation represents an interesting solution: it combines a highly resistant etchable ceramic that can be used with minimum thickness with a type of preparation that allows the preservation of a large amount of dental tissue, especially in the cervical area.

The present retrospective study aims to evaluate the clinical performance of LiDiSi CAD/CAM veneers with feather-edge margins, inserted over 4 years in a private dental practice.

MATERIALS AND METHODS

INCLUSION AND EXCLUSION CRITERIA

The present retrospective study was based exclusively on data collected from patients who had been treated with LiDiSi CAD/CAM veneers with feather-edge margins, in a single private clinic over 4 years (2015–2019). All the data were obtained and collected retrospectively from the analysis of the patients’ electronic

medical records, which presented all the necessary clinical information, being also accompanied in some cases by photographic and radiographic documentation. Further conditions for inclusion in this retrospective clinical study were the agreement to regularly attend the scheduled follow-up sessions when patients were recalled for professional oral hygiene treatment (every 6 months). Patients also agreed to undergo photographic checks and signed a specific consent, in addition to that required for the therapies. Exclusion criteria were patients treated with CAD/CAM-LiDiSi veneers with horizontal margins or with heat-pressed LiDiSi veneers; patients treated with analogue methods (i.e. through the capture of analogue impressions with trays and conventional materials) or not fully digital techniques; all patients who had no opposing dentition; and patients who did not give consent for enrolment. Edge-to-edge position of the front teeth was not considered as an exclusion criteria. However, in those patients, an increase of the width of the anterior arch was planned, where esthetically possible; if that was not possible, an increase of the vertical dimension of occlusion (VDO) was planned and obtained prosthetically, in order to obtain a sufficient restorative space and avoid any possible complication. The present retrospective clinical study was conducted under the respect of the principles of the Helsinki Declaration on Human Experimentation of 1975 (revision of 2008).

OPERATIVE PROTOCOL

The teeth were prepared with feather-edge margins and an overall reduction from 0.2 to 1 mm for the incisal surfaces. The preparation followed the technique presented by the same author in 2016,³¹ which allows careful control of the thickness (*Figure 1*) and excellent esthetic results even in the cervical third (*Figure 2*). The depth of the preparation was individualised, based on the characteristics of the case. The incisal overlap was performed when lengthening of the incisal margins was needed for esthetic or functional purposes. Provisional restorations were not provided except in cases where the preparation was deeper and more visible to the patient. The temporary restorations were prepared, where necessary, through a silicone index and cemented with a point adhesion technique. Preservation of the tooth structure was a priority in all cases, during both the preparation and finishing phases.

While preparing the tooth, the clinician (M.I.) employed a single retraction cord (Ultrapack[®], Ultradent, South Jordan, UT, USA or SilTrax[®], Pascal Dental, Bellevue, WA, USA) before the final optical impression that was captured with an intraoral scanner (Trios3[®], 3Shape, Copenhagen, Denmark). The choice of the thickness of the retraction cord was determined by the depth of the gingival sulcus. CAD software (DentalCAD[®], Exocad, Darmstadt, Germany) was used for digital design. The standard tessellation language (STL) files of the restorations generated within the CAD system were then processed by a milling unit (MCXL[®], Dentsply-Sirona, York, PA, USA), sintered and coloured. DiSiLi CAD/CAM blocks (E-Max CAD[®], Ivoclar Vivadent, Schaan, Liechtenstein) were used for all milling; the choice of the block was individualised on the basis of the clinical indications given by the colour

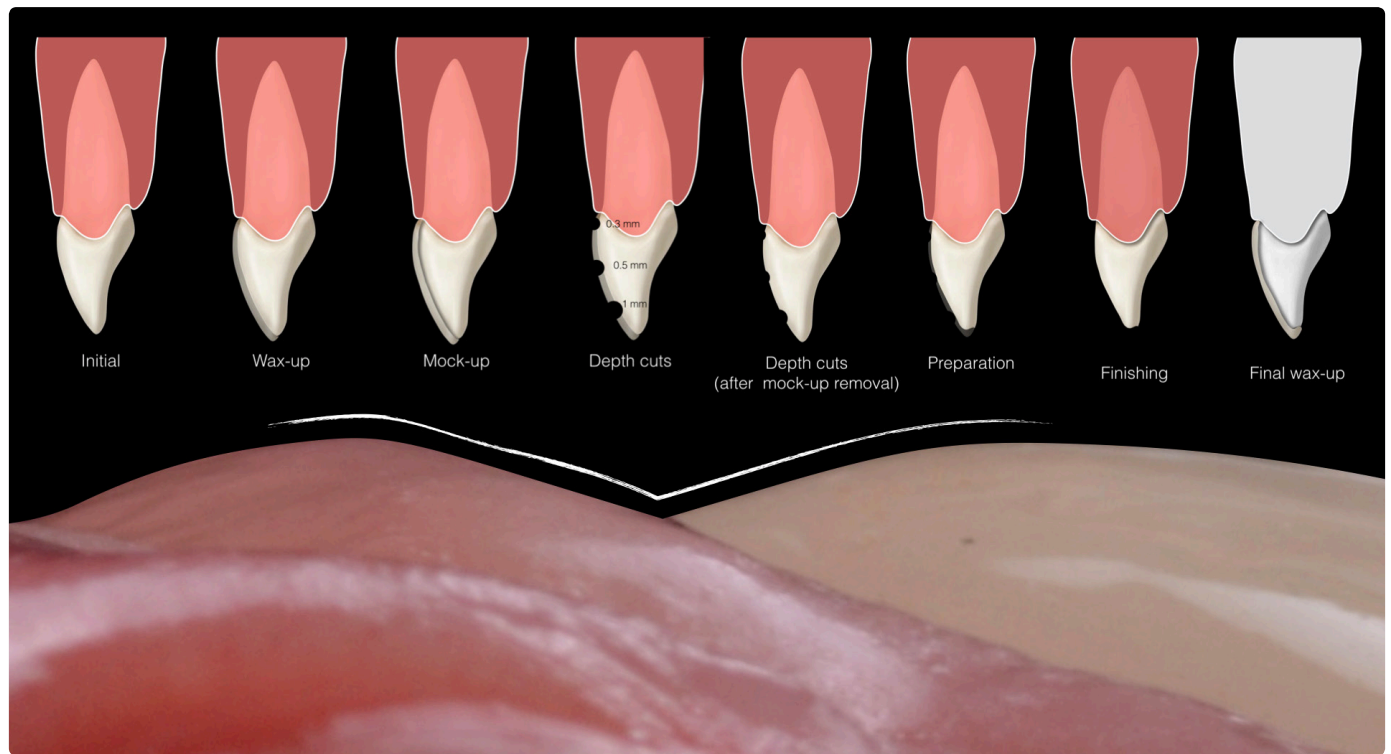


Figure 1: The workflow designed for vertical preparation for veneers. The study of the future emergence profile is a key point to be evaluated.

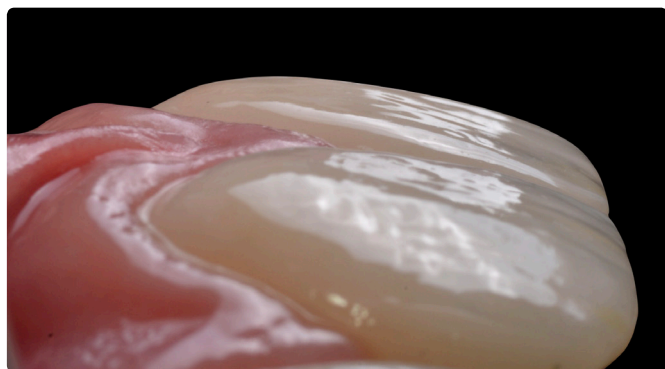


Figure 2: The final outcome of the restoration on the cervical third

and translucency of the teeth. All the indications provided by the manufacturer were respected, both in the production phase and in sintering and colouring. The veneers were checked in the laboratory on a 3D printed model (Form2®, Formlabs, Somerville, Boston, MA, USA) without removable dies, derived from the optical impression. In this phase, the printed model was used to perform only gross adjustments when needed, since the accuracy of such model is not enough to check marginal precision of the restorations.³² The technician, however, carefully evaluated the interproximal contact points, occlusion and, above all, marginal adaptation; small adjustments were made where necessary. Finally, cementation was performed without a rubber dam, as the operating field was isolated with retractors (OpraGate®, Ivoclar Vivadent), a high-speed suction system, silicone and Teflon® tapes. The clinician had to pay particular attention during cementation, since the lack of a defined preparation line could lead to errors in the positioning and therefore in the cementation of the

veneers. The etching of the restorations took place using 5% hydrofluoric acid (Porcelain Fix®, BJM Lab, or Yehuda, Israel) for 20 seconds, after which the veneers were washed with water, dried and silanized (Monobond-S®, Ivoclar Vivadent). Where there was a large amount of residual enamel, the tooth was subjected to a three-phase adhesive system treatment; conversely, the operator employed a single self-etching primer for dentin. Based on the final thickness of the restorations, the clinician chose between a light-curing resin cement (Variolink Veneer®, Ivoclar Vivadent) or a self-light-curing resin cement (Multilink Automix®, Ivoclar Vivadent). Initially, the operator gave a quick first hit of polymerisation for a few seconds; before the definitive hardening of the cement, he proceeded to eliminate its excesses from the buccal and proximal surfaces using a dental probe, dental floss and a surgical blade (12D surgical scalpel blade, Swann-Morton, Sheffield, UK). Subsequently, the polymerisation could be completed for a total time of not less than 3 minutes for each restoration, using a halogen curing light at 780 mW/cm² (Optilux 501®, Kerr, Orange, CA, USA). Once the cementation was complete, the clinician carefully checked the static and dynamic (protrusion and laterality) occlusion, in order to avoid any interference. The guidance was achieved also on veneers, with very smooth path, and avoiding an excessive stepness of the guidance. The clinician could perfect the final occlusal re-touches with conical and ovoid burs (grain size 100–125 µm) and polish the surfaces of the restoration with silicone discs (ceramic polish 9545 F®, Brasseler, Savannah, GA, USA) and felt wheels using polishing paste (Dia Glace diamond paste®, Yeti GmbH, Engen, Germany). A fully documented clinical case is presented in Figures 3–12.

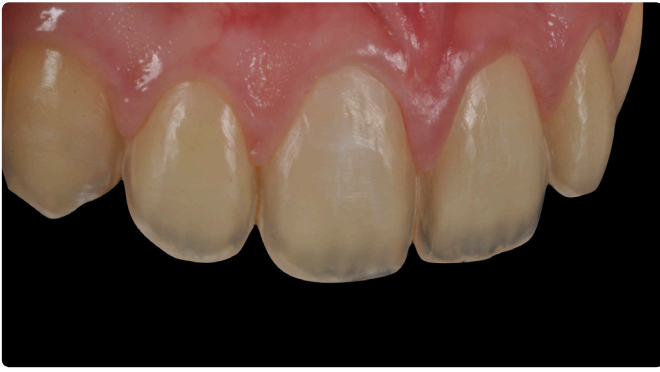

Figure 3: Vertical preparations for veneers.

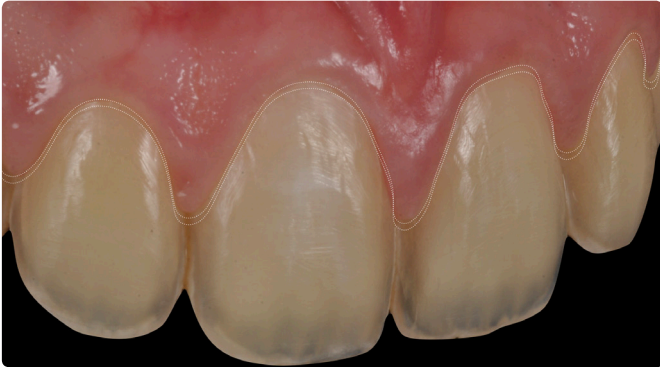

Figure 4: The main concept in vertical preparation is that there is a finishing area rather than a finishing line. The restoration could be designed on different finishing lines.

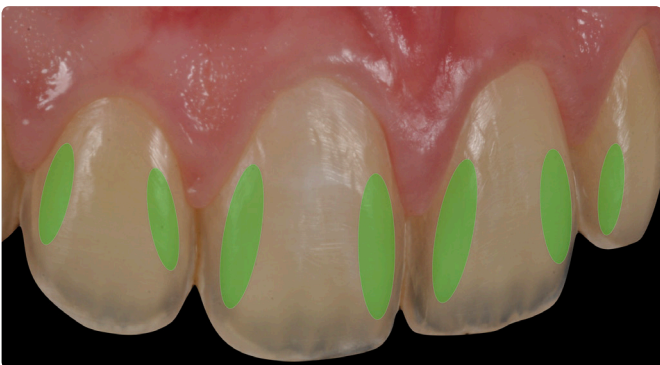


Figure 5: In minimal preparation design, the transition line zone should be checked in terms to have a proper thickness.

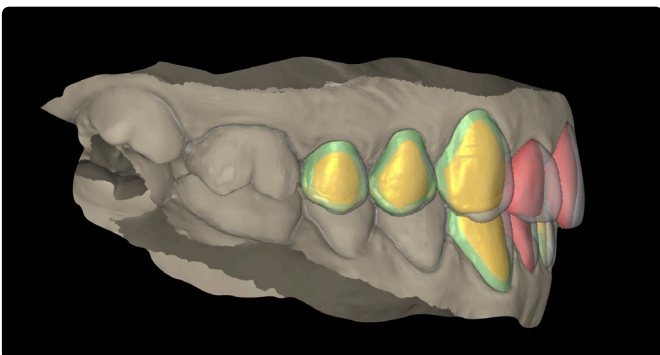


Figure 6: The finishing line is designed on the stl file.

After cementation, detailed post-operative instructions were provided to the patients. Patients were requested to pay special attention to daily oral hygiene procedures (brushing and

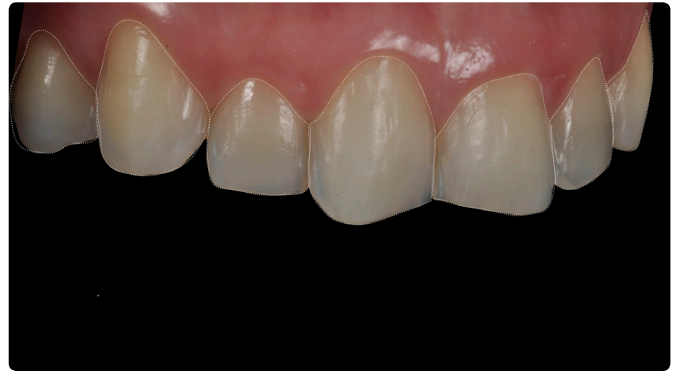

Figure 7: The most part of the preparation is on enamel, especially on the margin.



Figure 8: The restorations milled.

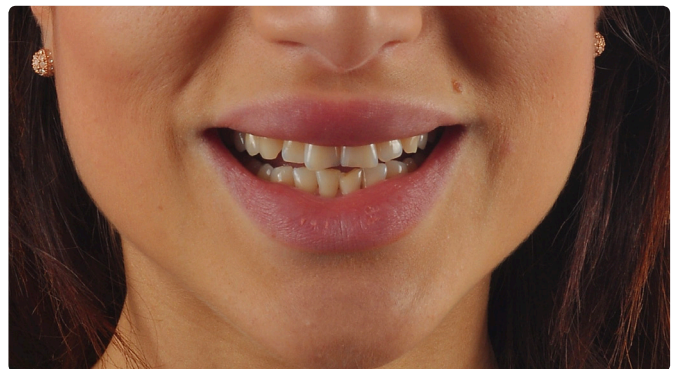

Figure 9: Pre-operative view.

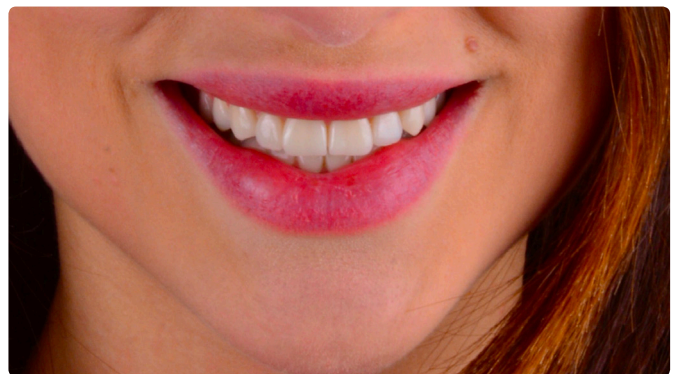

Figure 10: Post-operative view.

flossing). Patients were requested to pay attention in particular to the area where their veneers meet the gums, as plaque accumulation in that area must be avoided for the successful

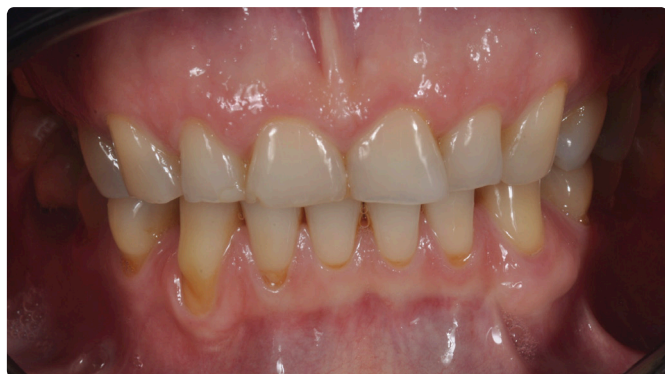

Figure 11: Pre-operative view.

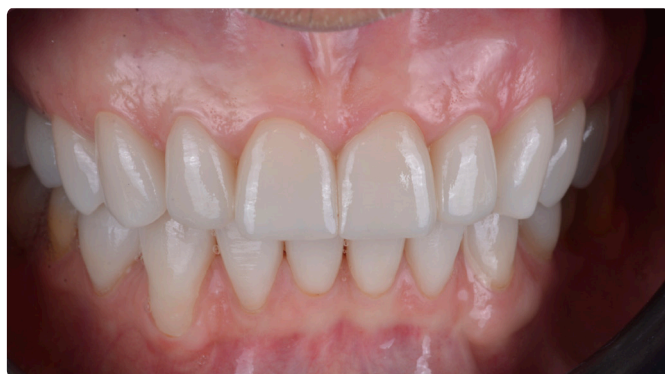

Figure 12: Post-operative view.

long-term survival of the restorations. The dental hygienist spent 20 minutes with each patient, explaining how to correctly brush and floss their teeth. In addition, patients were included in an annual follow-up program, and were requested to visit the dental office at least twice per year, for professional oral hygiene procedures. Finally, in the presence of compulsive habits (for example, nail biting) patients were asked to stop biting their nails; in the presence of parafunctions (clenching or bruxism) an occlusal night guard was provided to the patients, in order to protect the restorations from the undesired effects of the parafunction, and to provide a guide for the jaw so that muscles can relax and bite problems will not trigger the bruxing action.

OUTCOME VARIABLES

The outcome variables of this study were survival of the restorations, colour matching, quality of the ceramic surface, presence of marginal discolouration and marginal integrity. The last four variables were assessed using the modified California Dental Association (CDA) and Ryge criteria, as previously described.³¹ These criteria use four scores (Alpha = optimal, Bravo = sufficient, Charlie = insufficient, Delta = bad) to evaluate the quality of the restoration. One experienced prosthodontist (F.M.), who was not directly involved in the treatment of patients, assessed these variables during each follow-up session. Every examination was performed using an intraoral mirror, a sharp explorer, a periodontal probe (XP23/OW® Hu-Friedy, Chicago, IL, USA) and when requested, photographs and radiographs. The evaluation of the outcome variables occurred at different times. The first evaluation (T0) was performed at

the time of cementation (baseline). Re-evaluations were made every 6 months thereafter during routine professional hygiene appointments (T1 = 6 months recall, T2 = 1 year control, T3 = 18 months follow-up, T4 = 2 years follow-up, T5 = 30 months recall; T6 = 3 years follow-up; T7 = 42 months recall; T8 = 4 years follow-up). The final score assigned to the restoration and valid for the statistics was the one assigned during the last control visit. Infiltration due to abutment decay, core fracture, partial or complete debonding that exposed the tooth structure were the main reasons for veneer failure. The veneers were evaluated for apparent changes in their outward structural integrity (chips, cracks, fractures) and marginal integrity using a sharp dental explorer, in accordance with the modified CDA and Ryge criteria.³¹

STATISTICAL ANALYSIS

All data collected during subsequent follow-up visits and recorded in the individual patient records were used for the evaluation of the main outcomes of the study, i.e. the survival of the restorations, colour matching, quality of the ceramic surface, presence of marginal discolouration and integrity. The veneers' cumulative survival rate was assessed using the Cutler and Ederer analysis,³³ and life-table analysis for the analysis of the survival of the restorations were generated (overall, maxilla, mandible, anterior and posterior areas).

RESULTS

In total, 105 patients (64 female, 41 male) treated with 1075 LiDiSi CAD/CAM veneers with a knife-edge preparation in a 4-year period (January 2015 to January 2019) were enrolled in this retrospective clinical study. Among the veneers, 655 were cemented in the maxilla (130 central incisors, 127 lateral incisors, 124 canines, 85 first bicuspid, 85 second bicuspid, 63 first molars and 41 second molars), and 420 in the mandible (91 central incisors, 88 lateral incisors, 75 canines, 44 first bicuspid, 44 second bicuspid, 44 first molars and 34 second molars).

The survival of these veneers was investigated between January 2015 and January 2020, with a follow-up time ranging from 1 to 5 years (mean observation period: 30.8 months).

In total, only one adhesive failure was reported in this study, after 3 years of function, in a second maxillary premolar. This complication was managed by redoing the restoration, then luting again, checking the occlusion and avoiding any occlusal contact during lateral movement. No other failures were reported, and the cumulative survival rate of the restorations amounted to 99.83%. The cumulative survival rates with the Cutler and Eder table were summarized in Table 1-5.

All restorations were rated Alpha and Bravo (the highest scores), and no restorations were rated as Charlie or Delta (the lowest scores) on the modified CDA and Ryge criteria, i.e. the analysis of colour matching, quality of the ceramic surface, presence of marginal discolouration and marginal integrity.

Table 1. Overall life-table analysis for veneers survival.

Time interval (months)	Veneers at the start of the interval	Drop-outs during the interval	Veneers under risk	Failures during the interval	Survival rate within the period (%)	Cumulative survival rate (%)
0-12	1075	8	1067	0	100%	100%
12-24	885	4	881	0	100%	100%
24-36	579	6	573	1	99.83%	99.83%
36-48	358	3	355	0	100%	99.83%
48-60	250	2	248	0	100%	99.83%

Table 2. Cutler & Ederer life-table survival analysis for veneers placed in the maxilla.

Time interval (months)	Veneers at the start of the interval	Drop-outs during the interval	Veneers under risk	Failures during the interval	Survival rate within the period (%)	Cumulative survival rate (%)
0-12	655	5	650	0	100%	100%
12-24	514	2	512	0	100%	100%
24-36	365	4	361	1	99.73%	99.73%
36-48	227	2	225	0	100%	99.73%
48-60	199	2	197	0	100%	99.73%

Table 3. Cutler & Ederer life-table survival analysis for veneers placed in the mandible.

Time interval (months)	Veneers at the start of the interval	Drop-outs during the interval	Veneers under risk	Failures during the interval	Survival rate within the period (%)	Cumulative survival rate (%)
0-12	420	3	417	0	100%	100%
12-24	371	2	369	0	100%	100%
24-36	214	2	212	0	100%	100%
36-48	131	1	130	0	100%	100%
48-60	51	0	51	0	100%	100%

Table 4. Cutler & Ederer life-table survival analysis for anterior veneers (incisors and cuspids).

Time interval (months)	Veneers at the start of the interval	Drop-outs during the interval	Veneers under risk	Failures during the interval	Survival rate within the period (%)	Cumulative survival rate (%)
0-12	635	5	630	0	100%	100%
12-24	514	2	512	0	100%	100%
24-36	399	4	395	0	100%	100%
36-48	276	2	274	0	100%	100%
48-60	215	1	214	0	100%	100%

Table 5. Cutler & Ederer life-table survival analysis for posterior veneers (premolars and molars)

Time interval (months)	Veneers at the start of the interval	Drop-outs during the interval	Veneers under risk	Failures during the interval	Survival rate within the period (%)	Cumulative survival rate (%)
0-12	440	3	337	0	100%	100%
12-24	371	2	369	0	100%	100%
24-36	180	2	178	1	99.44%	99.44%
36-48	82	1	81	0	100%	99.44%
48-60	35	1	34	0	100%	99.44%

Table 6. Success of the survived restorations assessed at the last follow-up control, according to the modified CDA and Ryge criteria

	Alpha	Bravo	Charlie	Delta
Color matching	1064	10	0	0
Ceramic surface	1070	4	0	0
Marginal discoloration	1069	5	0	0
Marginal integrity	1070	4	0	0

Among the surviving veneers, the colour matching was rated Alpha (1064 veneers, 99.06%) and Bravo (10 veneers, 0.94%); the ceramic surface was rated Alpha (1070 veneers, 99.62%) and Bravo (4 veneers, 0.38%); the marginal discoloration was rated Alpha (1069 veneers, 99.53%) and Bravo (5 veneers, 0.47%); and the marginal integrity was rated Alpha (1070 veneers, 99.62%) and Bravo (4 veneers, 0.38%). These scores were assigned during the last follow-up session attended by the patients and summarised in Table 6.

DISCUSSION

This retrospective clinical study reported on the clinical outcomes of 1075 feather-edge LiDiSi veneers fabricated via a fully digital CAD/CAM protocol, cemented on 105 patients and followed for a period ranging from 1 to 5 years, with a mean observation period of 30.8 months. The statistical evaluation found a satisfactory cumulative survival rate of 99.83%, as a result of only one adhesive failure that occurred 3 years after cementation. This survival rate was comparable to those found by Aykor & Ozel,¹² Guess & Stappert³⁴ and, before them, Fradeani,^{11,35} who used heat-pressed ceramic veneers with a conventional preparation; and similar to that found by Imburgia *et al.*³⁶ in a previous study, where heat-pressed veneers with feather-edge margins were used.

In the last few years, the evolution of CAD software and hardware, such as intraoral scanners, milling units and 3D printers, has radically transformed the workflow in digital dentistry.

The process is now more reliable,^{37,38} and the restorative materials have evolved dramatically. LiDiSi is no exception.³⁹

In the present clinical study, almost all veneers (99.06%) were rated Alpha for colour-matching, with only a few (0.94%) rated Bravo. None was rated as Charlie or Delta.

This result shows an improvement with colour matching, at least when compared with the previous study³⁶ that used heat-pressed LiDiSi veneers. This outcome may be a direct consequence of the more careful control of the thickness during preparation. In fact, in the case of single discoloured teeth, a deeper preparation was performed, combined with the use of a low translucency or high opacity LiDiSi block. The outcome may also be the result of the properly designed digital mock-up and the use of Shade Navigation App®, an application that helps identify the correct shade and translucency of the restoration. The 10 veneers rated Bravo may have been a consequence of the very conservative and minimally invasive preparation, in the presence of some tooth discoloration. Because the same block of material was used for the all veneers for the same patient, the presence of a single discoloured tooth may have partially affected the colour matching of the restoration.

With regard to the quality of the ceramic surface, 99.62% of the restorations were rated Alpha, and only 0.38% of the restorations were rated Bravo, again with no Charlie or Delta recordings. CAD/CAM blocks have a high concentration of crystals, and this may contribute to the final excellent result. The Bravo rating of the 4 restorations (in 4 lower incisors) was the result of an excess of surface texture that was managed by the clinician through surface polishing.

Finally, the marginal discolouration and integrity also showed excellent results, with the former rated as Alpha in 99.53% of the restorations and Bravo in 0.47% of the restorations, and the latter rated as Alpha in 99.62% of the veneers and Bravo in 0.38% of the veneers, respectively. No Charlie or Delta recordings were reported for either marginal discolouration or integrity. These excellent results may be related to the feather-edge design and the minimally invasive preparation that exhibit smaller marginal gaps compared with the conventional preparation. With conventional preparations, the literature reports 9% microleakage 5 years after cementation.⁴⁰⁻⁴² In a recently published review, Petridis *et al.*⁴⁰ found that 9.5% of veneers showed marginal discolouration at 5 years. In another literature review, Morimoto *et al.*⁴¹ found a lower incidence of marginal discolouration because the authors included clinical studies in which the preparation was more conservative in their analysis. Morimoto *et al.*⁴¹ also found better clinical outcomes of glass-ceramic veneers (94%) and feldspathic porcelain veneers (87%), at least when compared with other reviews.^{40,42}

Our study highlights how feather-edge preparations through the mock-up, in the absence of marginal chamfers or shoulders, allow the clinician to preserve the enamel even in the cervical area, the most critical zone.³⁴ This minimally invasive preparation potentially preserves more enamel at the margins, leading to a more reliable bond. This is particularly evident at equigingival margins, where enamel is thin, and a conventional chamfer is likely to penetrate into dentine.⁴ On the other hand, from our experience, we suggest a minimum thickness of the restorations 0.3 mm in the marginal area to avoid any fracture during milling or distortion during sinterisation.

Various studies have demonstrated a relationship between ceramic fracture and insufficient thickness of the restoration.²⁴⁻²⁶ However, deep preparations expose a larger amount of dentin, and this represents a risk factor for debonding and microleakage.⁴³⁻⁴⁶ It should be noted that ceramic with a vitreous phase, ideal for adhesion, demands less tissue preparation: the more the tissues are preserved, the less the deflection of the tooth. This factor could explain the satisfactory clinical outcomes and reduced failure rates in the short- and medium terms. After adhesion, the tooth-ceramic interfaces are very strong: the ceramic is reinforced, and the tooth structure itself is strengthened.⁴⁷

Until now, even though LiDiSi crowns have been used with shoulderless preparations,²⁴ limited clinical data are available on the use of feather-edge margins on veneers.³⁶ However, vertical preparation combined with LiDiSi restoration represents a minimally invasive restorative solution with maximum preservation of tooth structure (due to the limited thickness of the crown in the cervical area). In addition, the high translucency of LiDiSi veneers allows minimising the thickness of the restoration, without affecting the mechanical resistance. This approach, empowered by the full digital workflow, can increase the efficiency of the treatment. Still it is not clear

if the minimal overcontour at the restoration margins may represent a risk factor for the onset of gingival inflammation or periodontal disease;¹⁹ with this approach, in the present study, an artificial cement-enamel junction was restored, with stable gingival profiles and no particular signs of inflammation.²⁰ However, the clinician needs to pay particular attention during cementation, since in the absence of a well-defined margin, the correct position of the veneers is granted only by the interproximal contacts, and the incisal overlap (when performed).

Finally, the success rate of the restorations in our present study was probably influenced by the flexural strength of LiDiSi, with a minimally invasive preparation characterised by a high degree of enamel preservation, both at the margins and on the tooth surface. In fact, only one veneer failed after 3 years of function: in this case, the static occlusal contacts were correct, but an interference during lateral movement was detected.

Although this study dealing with lithium disilicate CAD/CAM veneers with feather-edge margins included an adequate number of restorations (1075) cemented in a large sample of patients (105) and monitored for a period up to 5 years of follow-up, it has limits. Firstly, despite the much improved technology of intraoral scanners that have recently entered the market,⁴⁸ we must not forget that direct intraoral scanning is not the best solution in full arch impression capture, for which conventional techniques (impression in silicone or polyether) remain the gold standard.^{49,50} Therefore the most accurate way to treat patients with multiple CAD/CAM LiDiSi veneers (8-10) may be represented by a conventional analog impression, casting of the gypsum model and eventually scanning it with a desktop scanner.^{49,50} In full arch patients, conventional and hybrid procedures still guarantee higher accuracy, and it is key to remember it;⁵⁰ however, the advantages of direct intraoral scanning are considerable, since it eliminates the conventional impression (not pleasant to the patient), simplifies and standardizes procedures for the clinician (reducing errors related to bad analog impression-taking) and improves communication with the laboratory, saving time and money. For all these reason, the fact that clinically acceptable results can be obtained with direct intraoral scanning in full arch patients too is important, and it represents one of the major findings of the present clinical study. A retrospective design is not the best to address the reliability of a new clinical procedure, and prospective studies or randomised controlled trials (RCT) comparing the clinical outcomes of LiDiSi veneers fabricated via a traditional (analog), hybrid (digitization of a gypsum cast by means of a desktop scanner) and full digital workflow (direct intraoral scanning) would better investigate the validity of our protocol. Ideally, the patients should be followed for a longer period (7-10 years) to understand the success rates and the degree of complications. Therefore, further clinical studies with appropriate design and longer follow-up are needed to draw more specific conclusions about this innovative treatment protocol.

CONCLUSIONS

In our present retrospective clinical study, the cumulative survival rate for 1075 CAD/CAM LiDiSi veneers with feather-edge margins, fabricated using a fully digital workflow, was 99.83% (mean follow-up: 30.8 months), with only one restoration failing due to a traumatic event 3 years after cementation. Colour matching, quality of the ceramic surface, marginal discolouration and integrity were evaluated during the last follow-up session using the modified CDA and Ryge criteria. All metrics showed highly acceptable results, never falling below 99% 'Alpha'. No Charlie or Delta ratings were recorded for any of the parameters. These results demonstrate that this treatment protocol can achieve similar results to those reported for other margin designs or different kinds of restorations, allowing for minimally invasive tooth preparation and an excellent esthetic outcome. Although the survival analysis of this study is a useful reference regarding the medium-term capabilities of LiDiSi used in vertical tooth preparations, long-term RCTs should also be conducted, including an assessment of periodontal health.

ABBREVIATIONS

Porcelain laminate veneers (PLVs), Lithium disilicate (LiDiSi), Computer-aided design/ computer-assisted-manufacturing (CAD/CAM), California Dental Association (CDA), Standard tessellation language (STL); randomized controlled trials (RCT).

AVAILABILITY OF DATA AND MATERIALS

Data are available from the first author of the article, upon reasonable requests.

COMPETING INTERESTS

The authors declare no conflict of interests related to this study.

FUNDING

The present study was self-funded.

AUTHORS' CONTRIBUTIONS

Research Concept and Design: MI; Collection and/or Assembly of Data: MI; Data Analysis and Interpretation: FM; Writing the article: HL, FM; Critical Revision of the Article: MI, HL; Final Approval of the Article: MI, HL, FM.

ACKNOWLEDGEMENTS

The authors are grateful to the DLab Team and in particular to Alessandro Giglio, but also to Lorenzo Cattaneo, Pietro Pendo-la, Barbara Zaina for the technical competence and efforts. The authors would like to thank Dr. Elio Marino, for the bright vision and excellent competences that allowed to make this happens.

REFERENCES

- Dietschi D, Spreafico R. *Adhesive Metal-Free Restorations: Current Concepts for the Esthetic Treatment of Posterior Teeth*. Chicago: Quintessence, 1997.
- Chen JH, Shi CX, Wang M, Zhao SJ, Wang H. Clinical evaluation of 546 tetracycline-stained teeth treated with porcelain laminate veneers. *J Dent* 2005;**33**:3–8.
- Edelhoff D, Liebermann A, Beuer F, Stimmelmayer M, Güth JF. Minimally invasive treatment options in fixed prosthodontics. *Quintessence Int*. 2016;**47**:207–216.
- Gürel G. Porcelain laminate veneers: minimal tooth preparation by design. *Dent Clin North Am* 2007;**51**:419–431.
- Granell-Ruiz M, Fons-Font A, Labaig-Rueda C, Martínez-González A, Román-Rodríguez JL, Solá-Ruiz MF. A clinical longitudinal study of 323 porcelain laminate veneers. Period of study from 3 to 11 years. *Med Oral Patol Oral Cir Bucal* 2010;**15**:e531–e537.
- Land MF, Hopp CD. Survival rates of all-ceramic systems differ by clinical indication and fabrication method. *J Evid Based Dent Pract* 2010;**10**:37–38.
- Friedman MJ. A 15-year review of porcelain veneer failure – A clinician's observations. *Compend Contin Educ Dent* 1998;**19**:625–630.
- Dumfahrt H, Schäffer H. Porcelain laminate veneers. A retrospective evaluation after 1 to 10 years of service: Part II – Clinical results. *Int J Prosthodont* 2000;**13**:9–18.
- Aristides GA, Dimitra B. Five-year clinical performance of porcelain laminate veneers. *Quintessence Int* 2002;**33**:185–189.
- Smales RJ, Etemadi S. Long-term survival of porcelain laminate veneers using two preparation designs: a retrospective study. *Int J Prosthodont* 2004;**17**:323–326.
- Fradeani M, Redemagni M, Corrado M. Porcelain laminate veneers: 6 to 12-year clinical evaluation – a retrospective study. *Int J Periodontics Restorative Dent* 2005;**25**:9–17.
- Aykor A, Ozel E. Five-year clinical evaluation of 300 teeth restored with porcelain laminate veneers using total-etch and a modified self-etch adhesive system. *Oper Dent* 2009;**34**:516–523.
- Valenti M, Valenti A. Retrospective survival analysis of 261 lithium disilicate crowns in a private general practice. *Quintessence Int* 2009;**40**:573–579.
- Radz GM. Minimum thickness anterior porcelain restorations. *Dent Clin North Am* 2011;**55**:353–370.
- Edelhoff D, Brix O. All-ceramic restorations in different indications: a case series. *J Am Dent Assoc* 2011;**142**:145–195.
- Edelhoff D, Sorensen JA. Tooth structure removal associated with various preparation designs for posterior teeth. *Int J Periodontics Restorative Dent* 2002;**22**:241–249.
- Zarone F, Di Mauro MI, Ausiello P, Ruggiero G, Sorrentino R. Current status on lithium disilicate and zirconia: a narrative review. *BMC Oral Health*. 2019;**19**:134.
- Zarone F, Ferrari M, Mangano FG, Leone R, Sorrentino R. "Digitally Oriented Materials": Focus on Lithium Disilicate Ceramics. *Int J Dent*. 2016;**2016**:9840594.
- Cagidiaco EF, Discepoli N, Goracci C, Carboncini F, Vigolo P, Ferrari M. Randomized Clinical Trial on Single Zirconia Crowns with Feather-Edge vs Chamfer Finish Lines: Four-Year Results. *Int J Periodontics Restorative Dent*. 2019;**39**:817–826.

20. Ioannidis A, Bomze D, Hämmerle CHF, Hüsler J, Birrer O, Mühlemann S. Load-bearing capacity of CAD/CAM 3D-printed zirconia, CAD/CAM milled zirconia, and heat-pressed lithium disilicate ultra-thin occlusal veneers on molars. *Dent Mater.* 2020;**36**:e109–e116.
21. Hampe R, Theelke B, Lümekemann N, Stawarczyk B. Impact of artificial aging by thermocycling on edge chipping resistance and Martens hardness of different dental CAD-CAM restorative materials. *J Prosthet Dent.* 2020 Feb 27:S0022-3913(20)30048-2. doi: 10.1016/j.prosdent.2019.12.022. Online ahead of print.
22. Donmez MB, Yucel MT. Effect of monolithic CAD-CAM ceramic thickness on resin cement polymerization: An *in-vitro* study. *Am J Dent.* 2019;**32**:240–244.
23. Alves DM, Cadore-Rodrigues AC, Prochnow C, Burgo TAL, Spazzin AO, Bacchi A, Valandro LF, Rocha Pereira GK. Fatigue performance of adhesively luted glass or polycrystalline CAD-CAM monolithic crowns. *J Prosthet Dent.* 2020 Jul 5: S0022-3913(20)30250-X. doi: 10.1016/j.prosdent.2020.03.032. Online ahead of print.
24. Scutellà F, Weinstein T, Redaelli S, Cerutti A, Testori T, Özcan M. Reliability of Chair-side Monolithic CAD-CAM Generated Lithium Disilicate Single Crowns with Knife- Edge Finish Line: Up to 5-Year Retrospective Analysis of Clinical Performance. *Eur J Prosthodont Restor Dent.* 2020;**28**:94-97
25. Schmitter M, Seydler BB. Minimally invasive lithium disilicate ceramic veneers fabricated using chairside CAD/CAM: a clinical report. *J Prosthet Dent.* 2012;**107**:71–74.
26. Romanini-Junior JC, Hirata R, Bonfante EA, Bordin D, Kumagai RY, Fardin VP, Coelho PG, Reis AF. Monolithic CAD/CAM laminate veneers: Reliability and failure modes. *Dent Mater.* 2020;**36**:724–732.
27. Amsterdam M, Rossman SR. Technique and hemisection of multirrooted teeth. *Alpha Omega* 1960;**53**:4–15.
28. Cortellini D, Canale A, Souza RO, Campos F, Lima JC, Özcan M. Durability and Weibull Characteristics of Lithium Disilicate Crowns Bonded on Abutments with Knife-Edge and Large Chamfer Finish Lines after Cyclic Loading. *J Prosthodont* 2015;**23**:615–619.
29. Cortellini D, Canale A. Bonding lithium disilicate ceramic to feather-edge tooth preparations: a minimally invasive treatment concept. *J Adhes Dent* 2012;**14**:7–10.
30. Schmitz J, Cortellini D, Granata S, Valenti M. Monolithic lithium disilicate complete single crowns with feather edge preparation design in the posterior region: a multicentric retrospective study up to 12 years. *Quintessence Int.* 2017;**20**:601–608.
31. Imburgia M, Canale A, Cortellini D, Maneschi M, Martucci C, Valenti M. Minimally invasive vertical preparation design for ceramic veneers. *Int J Esthet Dent* 2016;**11**:460–471.
32. Czajkowska M, Walejewska E, Zadrozny L, Wieczorek M, Świączkowski W, Wagner L, Mijiritsky E, Markowski J. Comparison of Dental Stone Models and Their 3D Printed Acrylic Replicas for the Accuracy and Mechanical Properties. *Materials (Basel)* 2020;**13**:4066.
33. Cutler S.J, Ederer, F. Maximum utilization of the life table method in analyzing survival. *J Chronic Dis* 1958;**6**:699–712.
34. Guess PC, Stappert CF. Midterm results of a 5-year prospective clinical investigation of extended ceramic veneers. *Dent Mater* 2008;**24**:804–813.
35. Fradeani M. Six-year follow-up with Empress veneers. *Int J Periodontics Restorative Dent* 1998;**18**:216–225.
36. Imburgia M, Cortellini D, Valenti M. Minimally invasive vertical preparation design for ceramic veneers: a multicenter retrospective follow-up clinical study of 265 lithium disilicate veneers. *Int J Esthet Dent* 2019;**14**:286–298.
37. Mangano F, Shibli JA, Fortin T. Digital Dentistry: New Materials and Techniques. *Int J Dent.* 2016;**2016**:5261247.
38. Mangano F, Gandolfi A, Luongo G, Logozzo S. Intraoral scanners in dentistry: a review of the current literature. *BMC Oral Health.* 2017;**17**:149.
39. Imburgia M, Kois J, Marino E, Lerner H, Mangano FG. Continuous Scan Strategy (CSS): A Novel Technique to Improve the Accuracy of Intraoral Digital Impressions. *Eur J Prosthodont Restor Dent.* 2020; **28**:128-141.
40. Petridis HP, Zekeridou A, Malliari M, Tortopidis D, Koidis P. Survival of ceramic veneers made of different materials after a minimum follow-up period of five years: a systematic review and meta-analysis. *Eur J Esthet Dent* 2012;**7**:138–152.
41. Morimoto S, Albanesi RB, Sesma N, Agra CM, Braga MM. Main Clinical Outcomes of Feldspathic Porcelain and Glass-Ceramic Laminate Veneers: A Systematic Review and Meta-Analysis of Survival and Complication Rates. *Int J Prosthodont* 2016;**29**:38–49.
42. Layton D, Clarke M. A systematic review and meta-analysis of the survival of non-feldspathic porcelain veneers over 5 and 10 years. *Int J Prosthodont* 2013;**26**:111–124.
43. Çötört HS, Dündar M, Öztürk B. The effect of various preparation designs on the survival of porcelain laminate veneers. *J Adhes Dent* 2009;**11**:405–411.
44. Sadowsky SJ. An overview of treatment considerations for esthetic restorations: A review of the literature. *J Prosthet Dent* 2006;**96**:433–442.
45. Peumans M, Van Meerbeek B. Porcelain veneers: a review of the literature. *J Dent* 2000;**28**:163–177.
46. Gürel G, Sesma N, Calamita MA, Coachman C, Morimoto S. Influence of enamel preservation on failure rates of porcelain laminate veneers. *Int J Periodontics Restorative Dent* 2013;**33**:31–39.
47. Burke FJ, Fleming GJ, Nathanson D, Marquis PM. Are adhesive technologies needed to support ceramics? An assessment of the current evidence. *J Adhes Dent* 2002;**4**:7–22.
48. O'Toole S, Bartlett D, Keeling A, McBride J, Bernabe E, Crins L, Loomans B. Influence of Scanner Precision and Analysis Software in Quantifying Three-Dimensional Intraoral Changes: Two-Factor Factorial Experimental Design. *J Med Internet Res.* 2020;**22**:e17150.
49. Ender A, Zimmermann M, Mehl A. Accuracy of complete- and partial-arch impressions of actual intraoral scanning systems *in vitro*. *Int J Comput Dent.* 2019;**22**:11–19.
50. Osnes CA, Wu JH, Venezia P, Ferrari M, Keeling AJ. Full arch precision of six intraoral scanners *in vitro*. *J Prosthodont Res.* 2020;**64**:6–11.